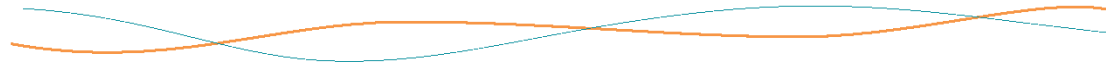



Le chirurgien face aux complications du cathétérisme



Pr Roland HENAINE
Chirurgien cardiaque pédiatrique
Hôpital Cardiologique Louis Pradel
Lyon



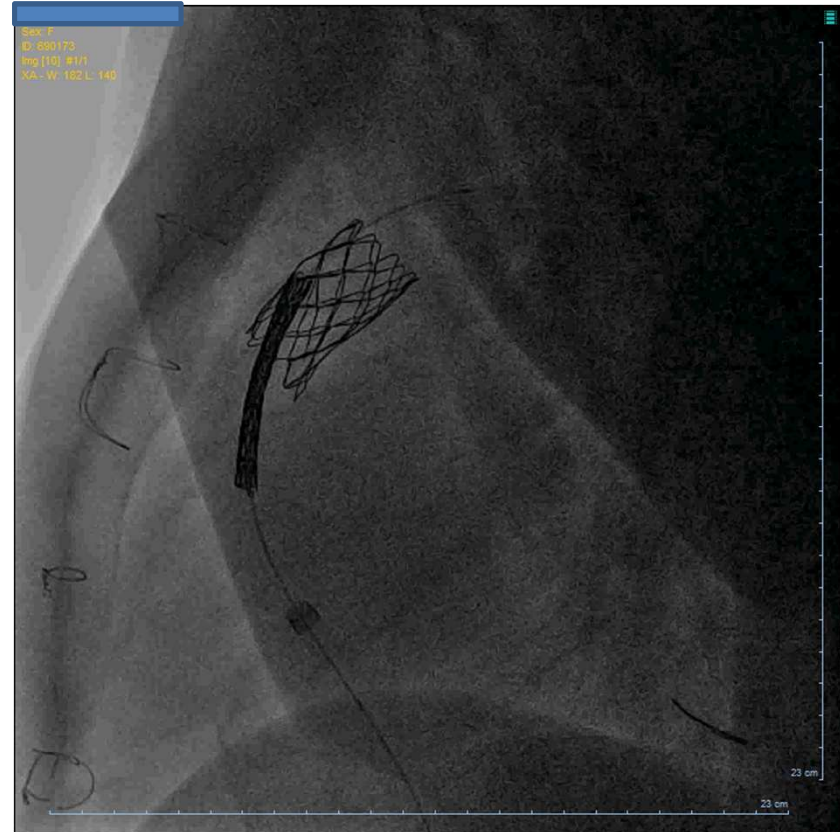
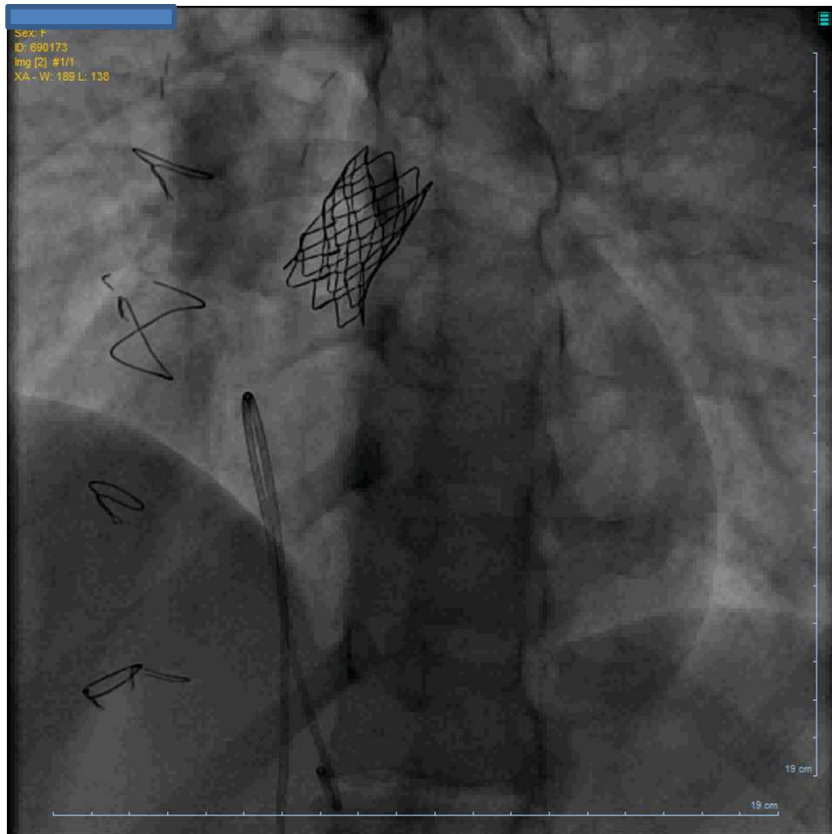
Conflits d'intérêts

➤ None

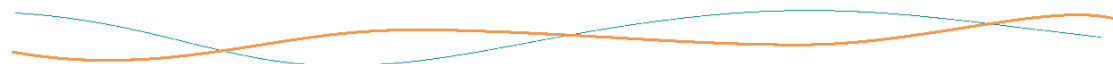
Cas Clinique

- Floriane M, 22 ans
- Antcdts:
 - Maladie de Willebrand
 - Fermeture chirurgical de CIV à 5 mois de vie
 - Valvulotomie aortique à 4 ans
 - Reintervention pour RA à 5 ans: IA post op
 - Ross à 10 ans
 - Dilatation par cathé de l'homogreffe pulmonaire à 21 ans avec mise en place d'un stent

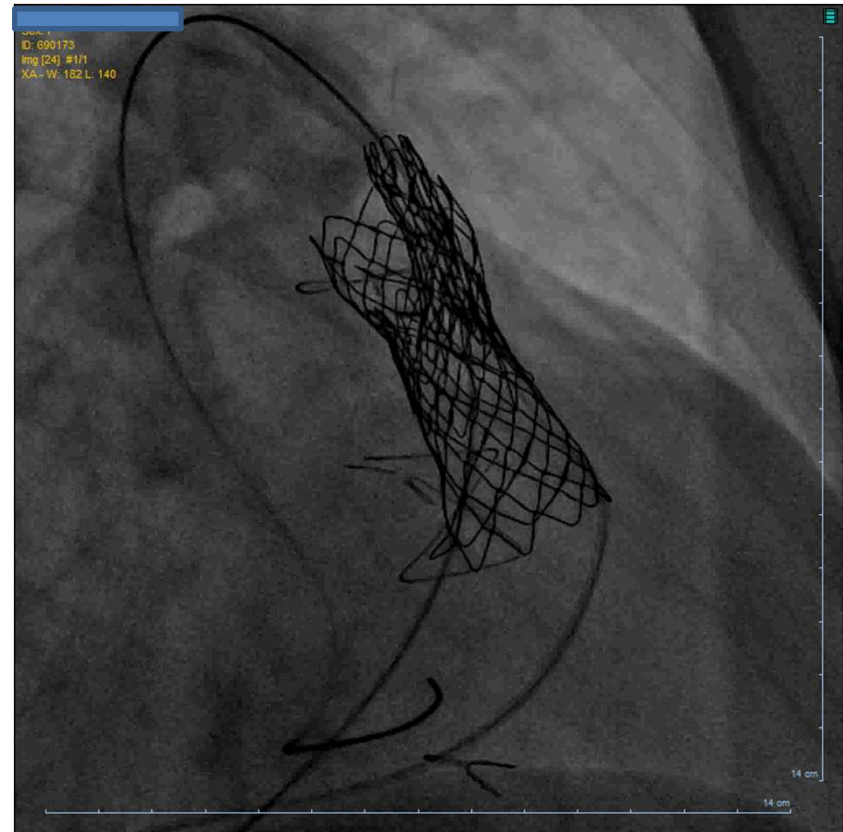
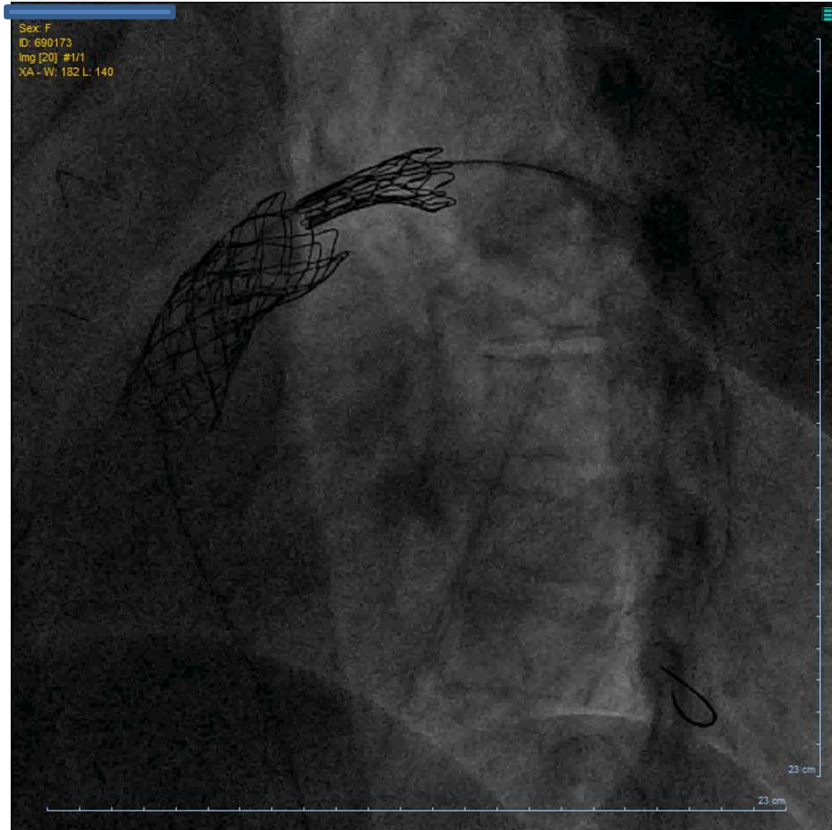
Cas Clinique



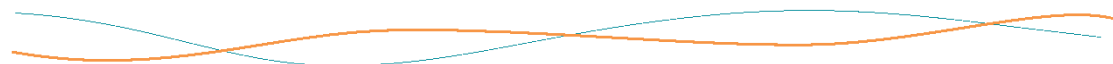
Un an plus tard, devant l'IP importante et le RP résiduel mal tolérés ,décision de mettre en place une Mélody pour éviter une 5ieme chirurgie...
Mais malheureusement...



Cathétérisme interventionnel



Lors de l'inflation, le ballon avance sur le stent qui ne peut être ouvert convenablement
Recharger le stent est impossible, si retrait risque de déchirer la tricuspide
Retrait chirurgical du matériel et RVP (hémodynamique stable)



Objectifs du cathé

1-diagnostic:

- Cardiac anatomy lesion
- Shunts, Qp/Qs
- Invasive measurement of pulmonary vascular hemodynamics
- Stenosis or regurgitation valvular evaluation
- Ejectional fraction

2- interventional:

- Atrial septostomy, balloon or blade
- Device closure of atrial septal defects
- Device closure of ventricular septal defects
- Valvuloplasty of aortic or pulmonary valve
- Valvuloplasty of mitral or tricuspid valve
- Angioplasty of pulmonary artery
- Stent placement in pulmonary artery
- Angioplasty of aorta or Stent placement in aorta
- Angioplasty/stent placement in PDA or aortapulmonary shunt
- Device occlusion of PDA or systemic shunt
- Angioplasty with or without stent of pulmonary or systemic venous vessel
- Percutaneous valve implantation, any position

Complications potentielles

- D'autant plus fréquentes que enfant plus jeune
- Arythmies (tachycardie jonctionnelle (>ES, Striadyne), flutter auriculaire (>overdrive, choc), BAVC (>PM), FV...
- Hypoxémie et acidose (examen long, hypoventilation, Fallot, cathé interventionnel difficile...)
- Hémorragie
- Perforation et tamponnade (>drainage), dissection aortique
- Fistules aorto-pulmonaire
- Compressions coronaires
- IA post valvulotomie mal tolérée
- Embolie gazeuse (air dans les cathéters): convulsions, troubles de repolarisation
- Spasmes et thromboses vasculaires (NNé, gros introducteurs, examen long > héparine systématique si abord artériel, polyglobulie...)
- Étirement plexus brachial (cathé long, curare, mauvaise position)

Exemple de la CIA

Catheterization and Cardiovascular Interventions 63:496-502 (2004)

- 50000 dans le monde
- Elévation St inf.
- Hématomes
- Embolisation (0.55%)
- Thrombose ≠ 0
- Troubles du rythme
- Troubles conductifs
- Infectieux (1 végétation)
- Erosions : 0.1 %

Erosion of Amplatzer Septal Occluder Device After Closure of Secundum Atrial Septal Defects: Review of Registry of Complications and Recommendations to Minimize Future Risk

Zahid Amin,^{1*†} MD, Ziyad M. Hijazi,^{2†} MD, John L. Bass,^{3†} MD, John P. Cheatham,^{4†} MD, William E. Hellenbrand,⁵ MD, and Charles S. Kleinman,^{5†} MD

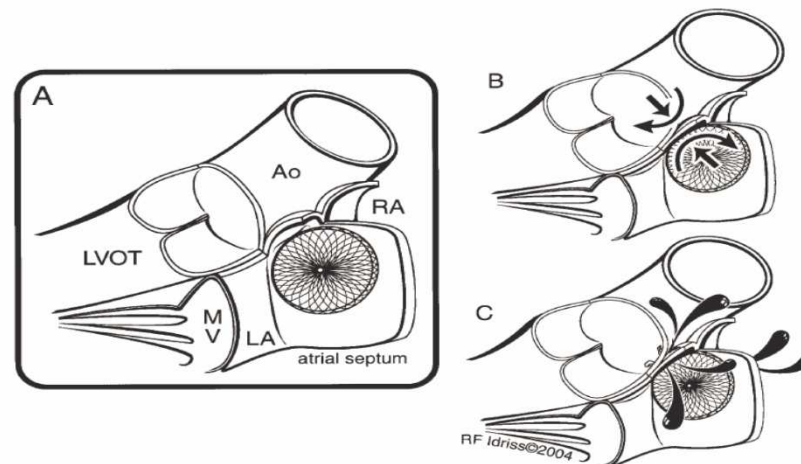


Fig. 3. A: ASO deployed in the ASD. Note the proximity of the free wall of the left and right atrium to the edge of the device. B: With every cardiac cycle, the edge of the device acts like a seesaw that may result in bruising the atria and/or the aorta. C: The device may ultimately erode the atrial wall and/or the aorta, causing hemodynamic compromise. LVOT, left ventricular outflow tract; MV, mitral valve.

Exemple de la CIV périmembraneuse

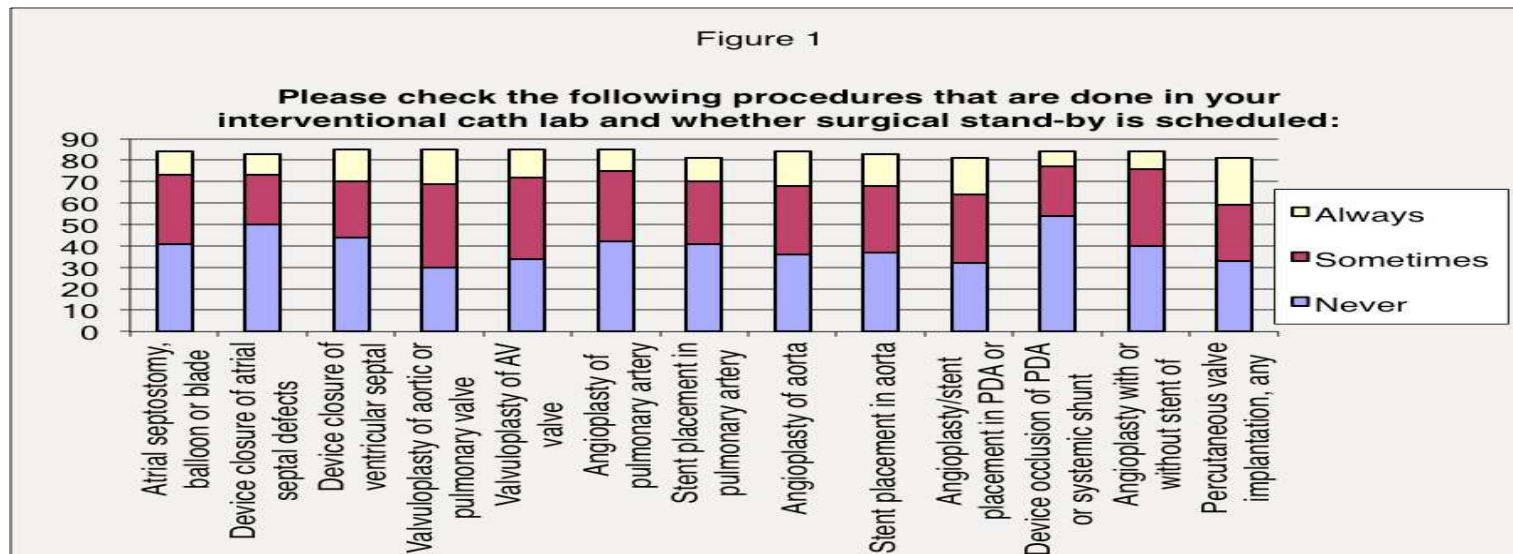
- 35 patients - 7.7 ans (1.2 à 54.4) – 25 Kg (8.3 à 110)
- QP/QS 1.8 (1 à 4) - Ø CIV 7mm (4 à15)
- 32 succès
- Pas de shunt 1 mois = 78% ; à 6 mois = 96 %
- Fluoroscopie 36' (14 à 191)
- Procédure 121' (67 à 276)
- 3 Complications graves - (8.6%)
- 1 BAV complet
- 1 Hémorragie périhépatique
- 1 Rupture de cordage tricuspide

FU et Hijazi J. Am. Coll. Cardiol 2006 ; 47 : 319-25

Surgical Standby for Complications in the Pediatric Cardiac Catheterization

Gerald A. Bushman, Mari K. Baldwin: *CONGENITAL CARDIOLOGY TODAY* April 2015; Volume 13; Issue 4 North American Edition

- Despite the availability of guidelines for pediatric cardiac centers
- the standards do not specifically address the availability of surgical backup
- A survey was constructed with the Congenital Cardiac Anesthesia Society
- Eighty-five centers were analyzed



Surgical Standby for Complications in the Pediatric Cardiac Catheterization

Gerald A. Bushman, Mari K. Baldwin: *CONGENITAL CARDIOLOGY TODAY* April 2015; Volume 13; Issue 4 North American Edition

Figure 2

The volume of pediatric cardiac interventional procedures done in the catheterization lab of my institution each year is:

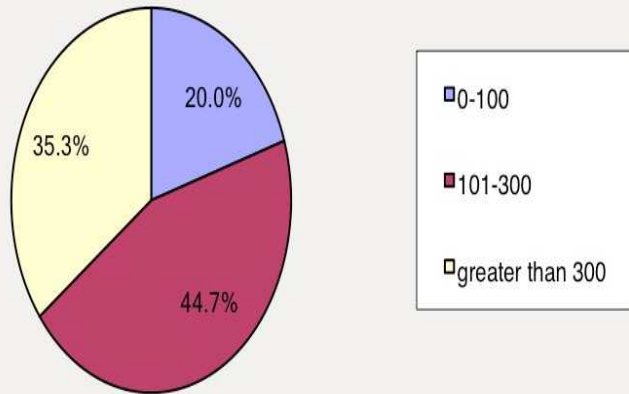
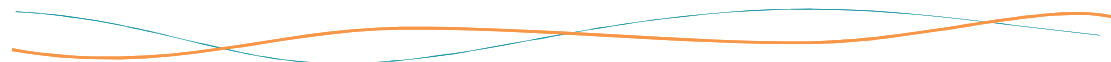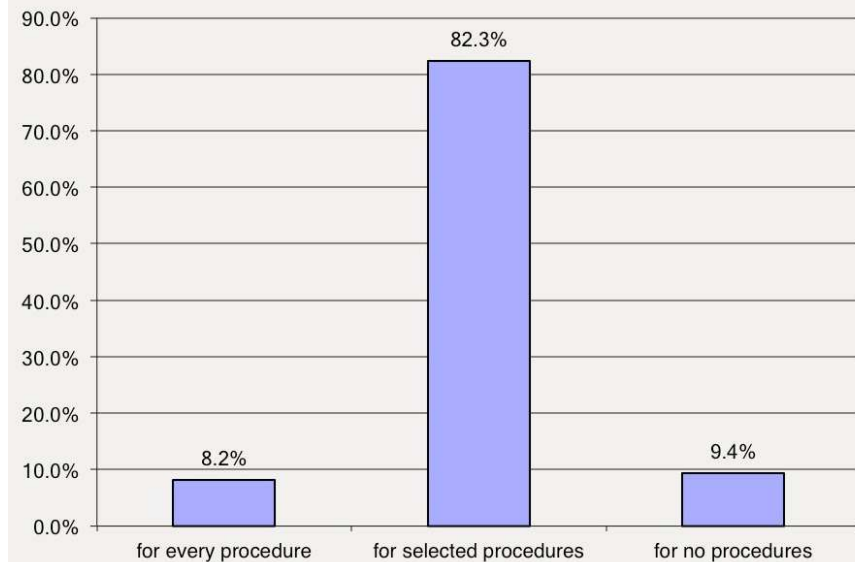


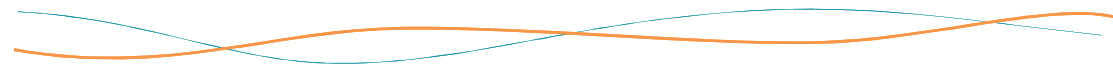
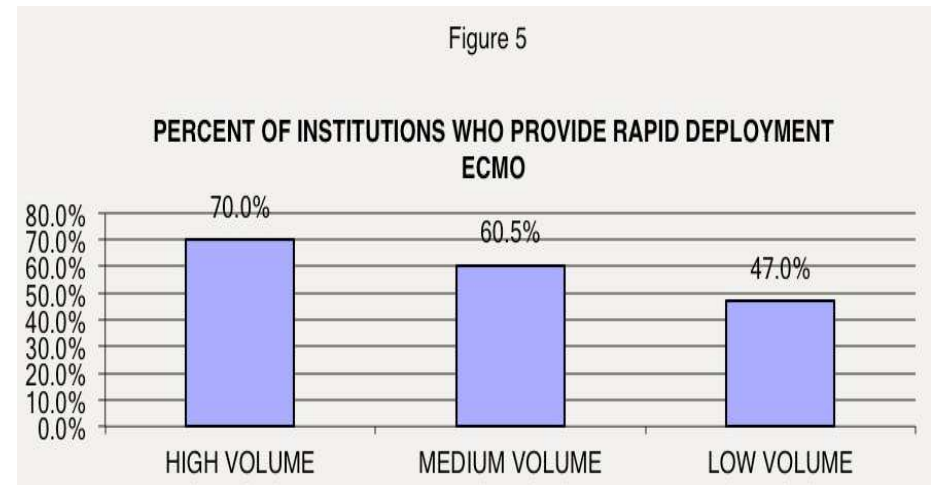
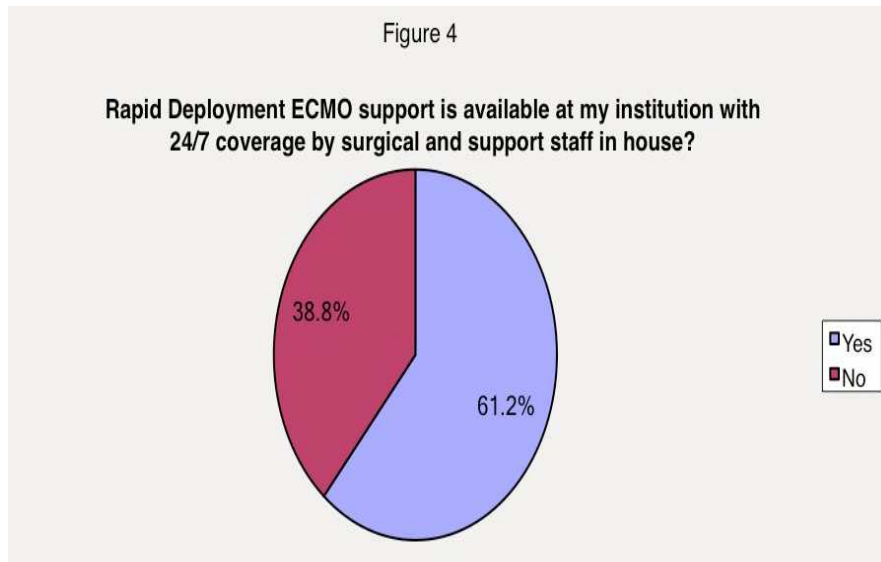
Figure 3

Surgical standby is available and scheduled



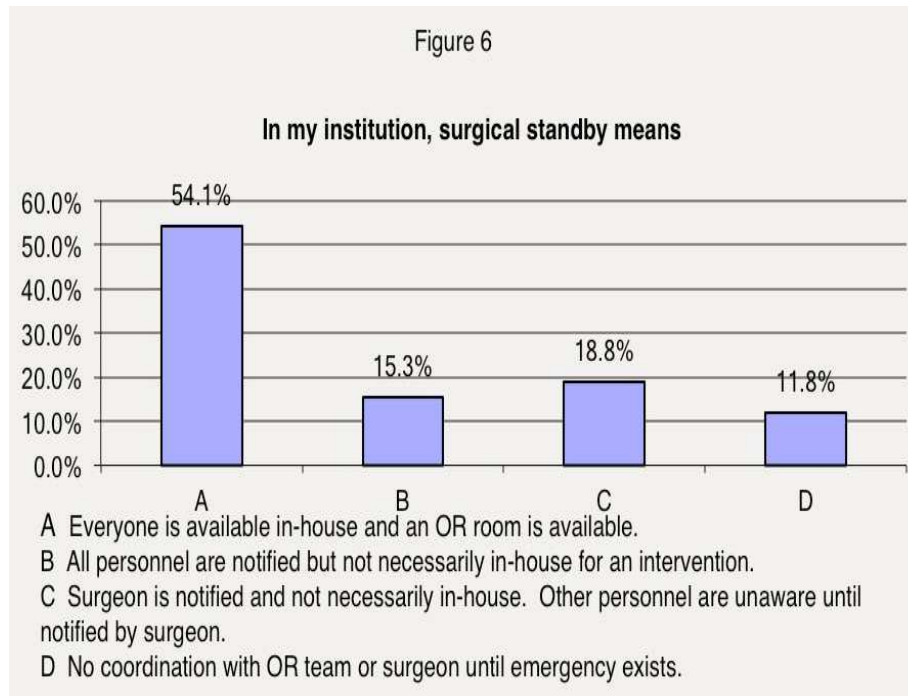
Surgical Standby for Complications in the Pediatric Cardiac Catheterization

Gerald A. Bushman, Mari K. Baldwin: *CONGENITAL CARDIOLOGY TODAY* April 2015; Volume 13; Issue 4 North American Edition

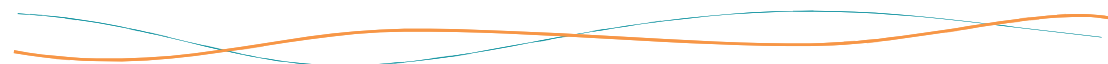


Surgical Standby for Complications in the Pediatric Cardiac Catheterization

Gerald A. Bushman, Mari K. Baldwin: *CONGENITAL CARDIOLOGY TODAY* April 2015; Volume 13; Issue 4 North American Edition

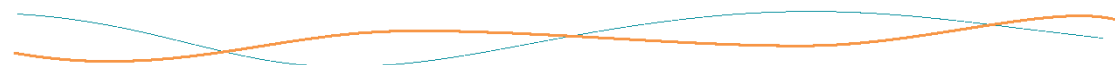
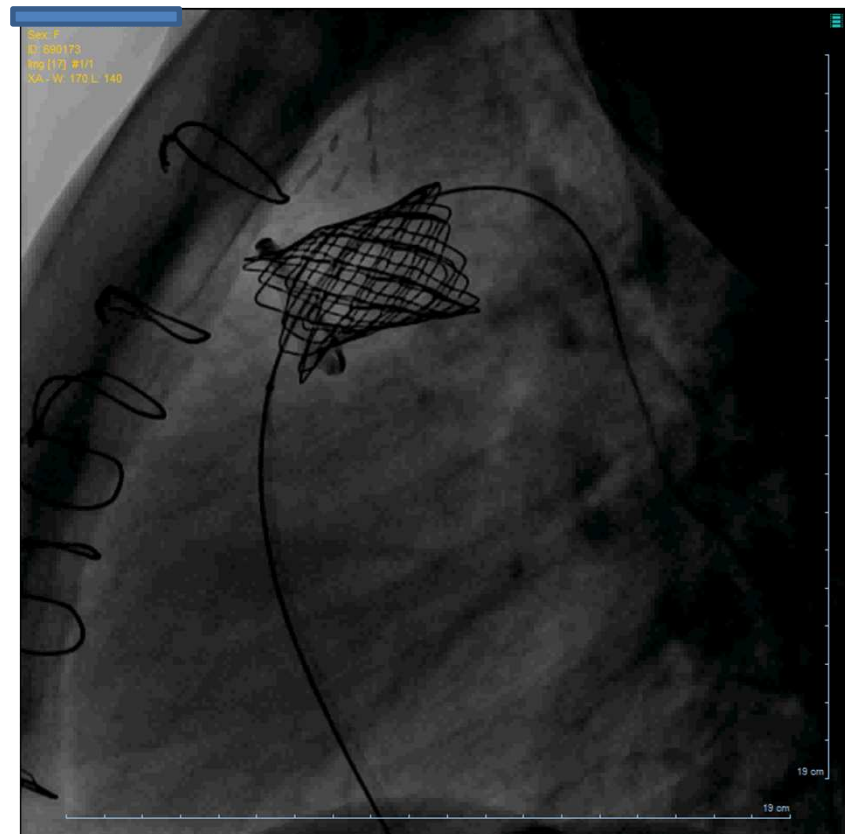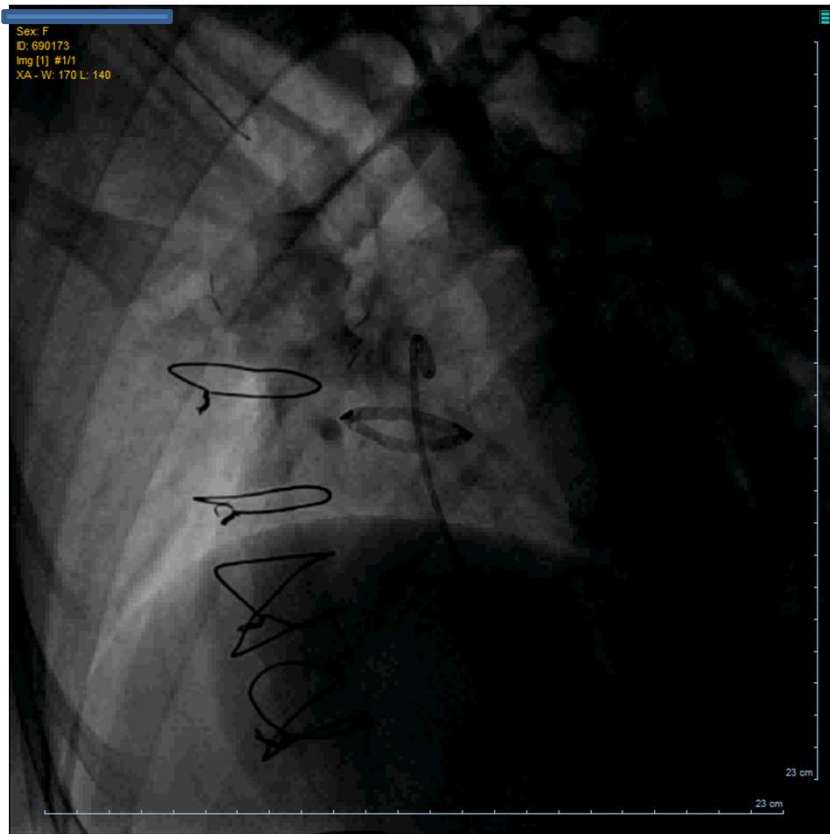


- Major and minor adverse events occur in up to 9%
- Events requiring surgical rescue are described to be “rare,” 2-4% of patients
- The importance of rapid learning curve and high volume
- Some institutions are underprepared for rare, but critical events
- While others may devote unnecessary resources to the same problems



Cas Clinique, épilogue: le chirurgien a aussi besoin du cathéteriseur!

Quatre ans plus tard ,à 26 ans, devant une dégradation précoce de la prothèse, elle bénéficie (avec succès!) de la pose d'une Mélody



Conclusion

- Complémentarité
- Heart Team: discuter en amont
- Protocoliser le stand by

REFERENCES

- ***Gerald A. Bushman, Mari K. Baldwin: CONGENITAL CARDIOLOGY TODAY
April 2015; Volume 13; Issue 4 North American Edition***
- ***Godard F. Cathéterisme interventionnel chez le nouveau né et l'enfant. EMC
Cardiologie, 11-940-J-10, 2010***
- ***F. Sassolas, catheterisme interventionnel congenital chez l'adulte, DU régional des
cardiopathies congénitales, Rhones-Alpes-Auvergne***
- ***J.R. Lussion, catheterisme interventionnel congenital chez l'adulte, DU régional des
cardiopathies congénitales, Rhones-Alpes-Auvergne***

Des questions?

Pr Roland HENAINE
roland.henaine@chu-lyon.fr

www.chircardio-lyon.org



Université Claude Bernard  Lyon 1



Hôpitaux de Lyon